Covered Socket Residuum (CSR)

A patient-oriented summary of post-extraction healing, terminology and three-dimensional assessment

1. Definition and clinical context

Covered Socket Residuum (CSR) is a term proposed in a 2026 review for a former tooth socket that has a mineralized bony covering near the gum, but retains a less-mineralized or non-mineralized area deeper inside. The gum may look healed even though the socket has not filled completely with mineralized bone.



Figure 1 [1]. Cross-section of CSR: **green** = new bone; **brown** = incompletely mineralized area beneath the bony covering. Such areas may contain soft tissue or marrow, not an empty hole.

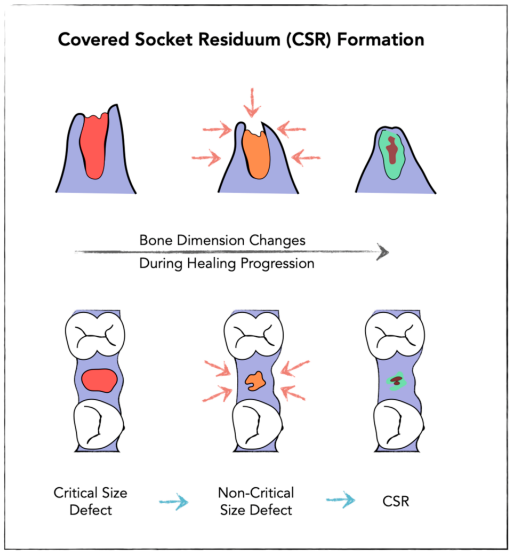

Figure 3 [1]. Proposed socket-healing sequence. Top: side view; bottom: view from above. The socket narrows and bone forms over its upper part; a less-mineralized area can remain underneath. This is not an inevitable outcome.

A scan finding is not automatically a disease
The review proposes that CSR may be a physiological healing pattern, including in people without symptoms. CSR alone does **not** prove infection, dead bone, the cause of pain or a need for surgery.

2. Terminology: cavitation, FDOJ, NICO and CSR

Cavitation	A broad, older descriptive word used for cavity-like or poorly mineralized jawbone areas. It does not identify one specific disease.
FDOJ / NICO	FDOJ means fatty degenerative osteolysis of the jawbone. NICO refers to neuralgia-inducing cavitational osteonecrosis. These are proposed pathological diagnoses discussed in older literature, not conclusions that a scan alone can establish.
CSR	A newer, descriptive term for a particular post-extraction imaging pattern. It is **not simply a replacement name for every cavitation, FDOJ or NICO.** In the review, pathological diagnoses require tissue assessment and clinical correlation.

doi:10.3390/bioengineering13010106

Healing and Three-Dimensional Assessment

An example of CBCT-based visualization and its role in clinical assessment

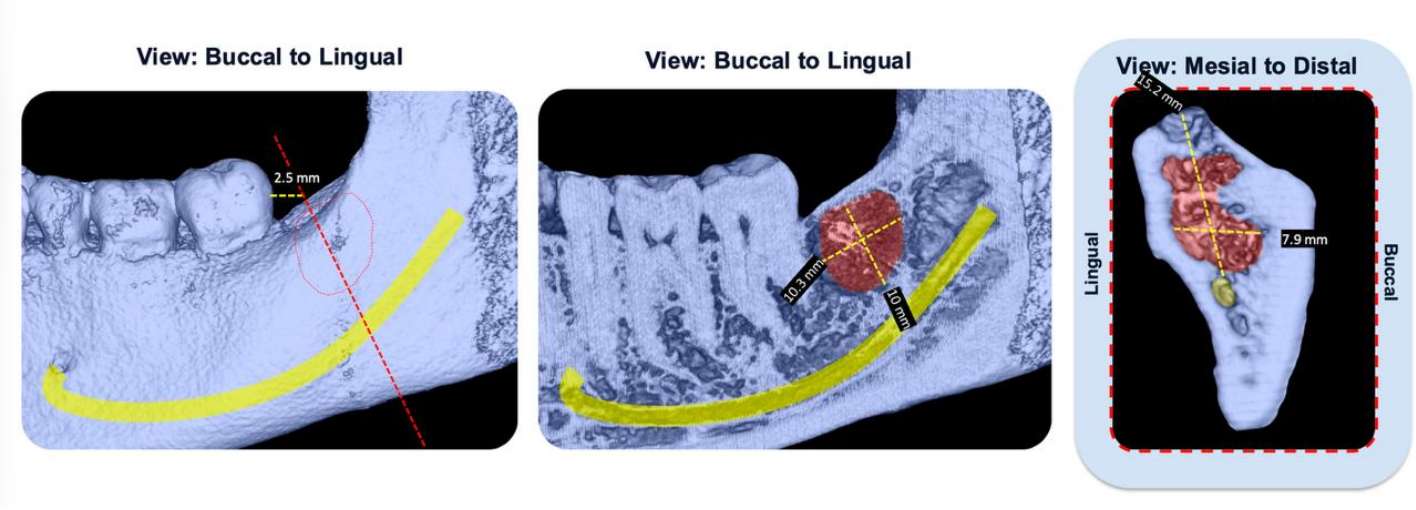

Visiogenics report example. Different views show the outer jaw and internal structures. The red/brown highlighted region is the area being visualized; the yellow structure marks the mapped nerve canal. Measurements belong to this example, not to the reader. Colours are visualization overlays, not a test result for infection.

3. Assessment and visualization

1. History and clinical examination
Assessment considers previous extractions, healing time, symptoms and future dental plans. Other causes of pain or abnormal imaging must also be considered.

2. CBCT imaging when indicated
Cone-beam computed tomography provides 3D X-ray views of the former socket, upper bony covering and surrounding anatomy. A 2D X-ray may not show the full internal pattern.

3. Visiogenics visualization
CBCT data can be submitted for additional 3D visualization to help clinicians inspect and explain internal bone structure. This is not a separate test for bacteria or inflammation.

4. Interpret everything together
The clinician combines the images and visualization with examination findings and treatment goals. Selected findings may need specialist review or tissue examination.

Interpretation and limitations of Visiogenics
Visiogenics describes its service as visualization that complements professional clinical evaluation, **not a stand-alone diagnostic service or treatment recommendation**. A colour-coded or low-density area does not by itself prove infection, FDOJ/NICO or a link to symptoms elsewhere in the body. [2]

4. Clinical decisions and remaining uncertainties

CSR does **not** automatically require treatment. Depending on the findings, options may include observation, further assessment, or treatment when there is a specific clinical reason. If an implant is planned, the clinician assesses whether there is enough suitable bone for support. When surgery is indicated, tissue analysis may help clarify what is present; cleaning and regenerative care are individualized.

What is still being studied? This paper is a narrative review, not a definitive treatment guideline. Most evidence is observational. Links to systemic inflammation, effects on implant outcomes and the best prevention or treatment strategies need stronger clinical studies. The paper does not establish that treating CSR improves general health.

Sources & diagram credit
[1] Ghanaati S. et al. *Jawbone Cavitations: Current Understanding and Conceptual Introduction of Covered Socket Residuum (CSR).* Bioengineering 2026;13:106. doi:10.3390/bioengineering13010106. Figures 1 and 3 reproduced under CC BY 4.0; explanatory captions simplified for this summary.
[2] Ghanaati Education / Visiogenics service description, accessed 25 October 2026. Assessment steps are an educational explanation, not a validation study of Visiogenics.